

SENSORY

8.6 Cortical Somatosensory Areas

Primary somatosensory cortex receives input from the ventral posterior nucleus and from other thalamic nuclei carrying somatosensory information. It is located in the *postcentral gyrus* of the left and right parietal lobes.

The primary somatosensory cortex of each hemisphere is laid out *somatotopically*; that is, it is laid out according to a map of the body. Each primary somatosensory cortex is a map of the contralateral side of the body. Each somatotopic map is distorted; the largest areas of primary somatosensory cortex receive input from parts of the body, such as the mouth, face, and hands, that are capable of fine tactual discrimination. The somatotopic cortical map is often referred to as the **somatosensory homunculus** (*homunculus* means *little man*).

Much of the output of primary somatosensory cortex is conducted to **secondary somatosensory cortex**. Secondary somatosensory cortex is located just inferior to primary somatosensory cortex in the postcentral gyrus; much of it is hidden from view in the lateral fissure. Like primary somatosensory cortex, the two areas, left and right, of secondary somatosensory cortex are somatotopically organized. Because each receives input from both left and right primary somatosensory cortex, each responds to somatosensory signals from either side of the body. Much of the output of the secondary somatosensory cortex is conducted to the posterior parietal association cortex.

Primary somatosensory cortex

The areas of cerebral cortex, one left and one right, that receive somatosensory input from the thalamus, largely from the ventral posterior nuclei; primary somatosensory cortex is located in the postcentral gyrus of each hemisphere.

Somatosensory homunculus (HOE mung kyul)

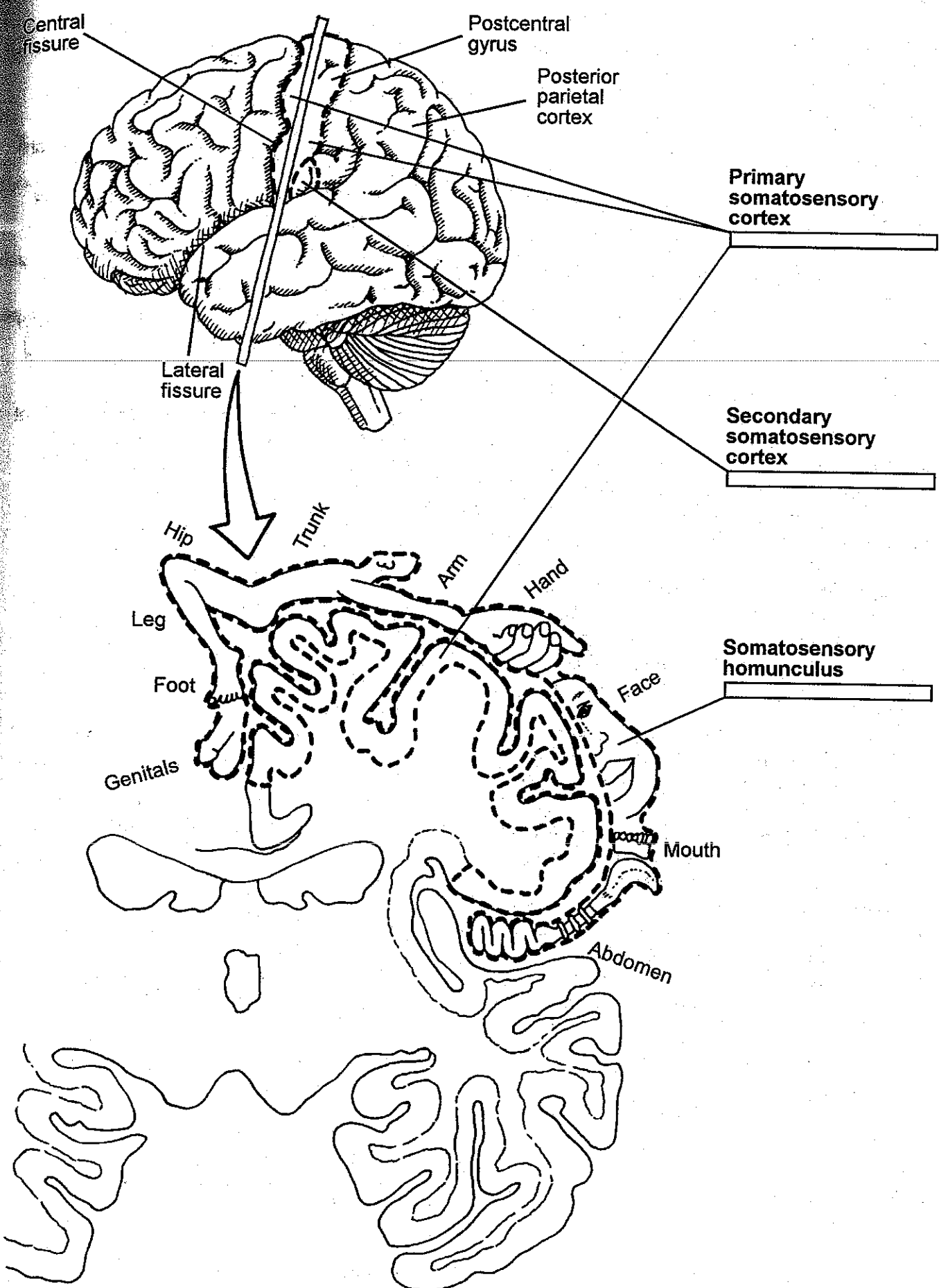
The somatotopic maps that constitute primary somatosensory cortex.

Secondary somatosensory cortex

The areas of cortex in each hemisphere that receive most of their input from primary somatosensory cortex; they are located in the postcentral gyri just inferior to primary somatosensory cortex.

Coloring notes

First, color the primary somatosensory cortex and secondary somatosensory cortex in the lateral view of the brain, that is, in the top illustration. Then, in the coronal section, color the primary somatosensory cortex and the somatosensory homunculus (the map of somatosensory input to the primary somatosensory cortex).





8.1 Visual System: From Eye to Cortex

Light enters the eye through the pupil and strikes the **retina**, the five-layered neural structure that lines the back of the eyeball. The last of these layers to be reached by the light contains the visual receptors. When the visual receptors are stimulated by the light, they produce signals that are conducted back through the retina to the first layer, which is composed of *retinal ganglion cells*. The retinal ganglion cells are the only retinal neurons with axons; their axons course across the inner surface of each eyeball and exit in a bundle, which is the **optic nerve** (i.e., the 2nd cranial nerve).

Most of the retinal ganglion cell axons pass through the **optic chiasm**, which is located on the inferior surface of the brain, just below the *hypothalamus*. At the optic chiasm, half the axons *decussate* (i.e., cross over to the other side of the brain), and half do not. Those with cell bodies in the medial *hemiretinas* (i.e., the medial half of each retina) decussate; those with cell bodies in the lateral hemiretinas do not. As a result, of this arrangement, information from your left visual field and right hemiretinas is conducted to your right hemisphere, and information from your right visual field and left hemiretinas is conducted to your left hemisphere, regardless of which eye it enters.

From the optic chiasm, the retinal ganglion cell axons enter the brain in two bundles, which are now referred to as the **optic tracts**. The neurons of the optic tracts terminate in the **lateral geniculate nuclei** of the thalamus. The axons of lateral geniculate nuclei neurons project via the **optic radiations** to the ipsilateral *primary visual cortex*.

The spatial relations among fibers leaving the surface of the retina are maintained all along the visual pathways to the primary visual cortex. As a result, the surface of the primary visual cortex is organized *retinotopically*, that is, its surface is laid out like a map of the surface of the retina, with the right visual cortex mapping the right hemiretinas and the left visual cortex mapping the left hemiretinas.

Retina

The five-layered neural structure that lines the back of each eyeball; the furthest retinal layer from the pupil contains the visual receptors, and the closest contains the retinal ganglion cells.

Optic nerves

The bundles of retinal ganglion cell axons that leave each eyeball; the second cranial nerves.

Optic chiasm (KYE az im)

The X-shaped midline structure on the inferior surface of the hypothalamus; the retinal ganglion cell axons originating in the medial hemiretinas decussate via the optic chiasm.

Optic tracts

The tracts, left and right, that project from the optic chiasm to the lateral geniculate nuclei; they are composed of the axons of retinal ganglion cells.

Lateral geniculate nuclei

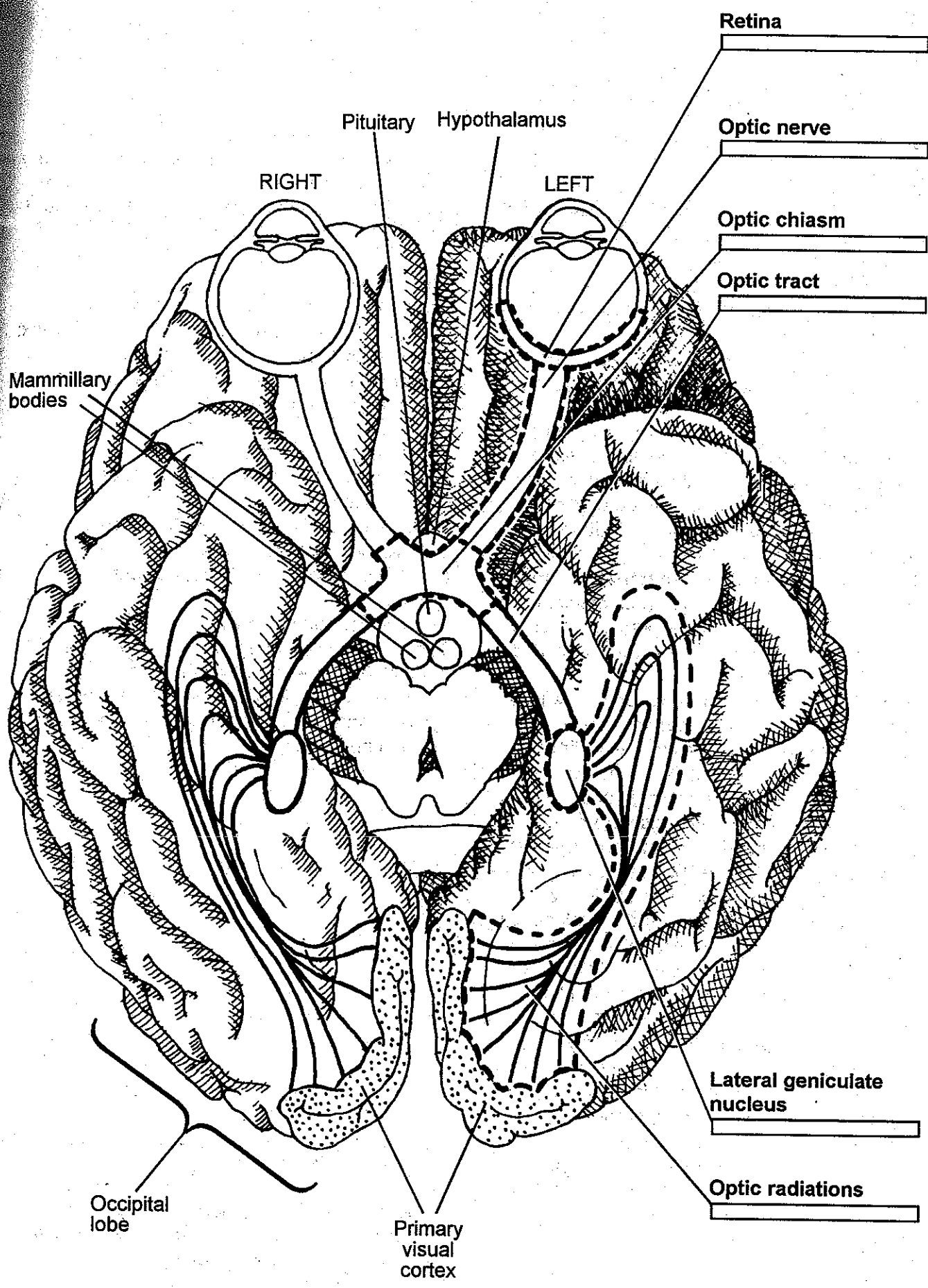
The thalamic nuclei that relay visual information from the optic tracts to the ipsilateral primary visual cortex via the optic radiations.

Optic radiations

The diffuse neural pathways from each lateral geniculate nucleus to the primary visual cortex of the same hemisphere.

Coloring notes

First, color the left retina—the one on the right side of the illustration, which has been drawn from the inferior perspective. Then, color each successive stage in the left visual pathway: optic nerve, optic chiasm, optic tract, lateral geniculate nucleus, and optic radiations. When you have finished coloring the visual system of the left hemisphere, color the visual system of the right hemisphere using the same colors.



Retina

Optic nerve

Optic chiasm

Optic tract

Lateral geniculate nucleus

Optic radiations

Pituitary Hypothalamus

RIGHT

LEFT

Mammillary bodies

Occipital lobe

Primary visual cortex



8.2 Cortical Visual Areas

Primary visual cortex constitutes much of the cortex of the occipital lobes although it is largely hidden from view in the *longitudinal fissure*; it is the gateway of visual input from the thalamus to the cerebral cortex. Primary visual cortex is sometimes called *striate cortex* because it has a visible stripe in layer 4, where the optic radiations from the thalamus synapse (*striate* means *striped*).

From the primary visual cortex, visual signals are conducted through numerous areas of secondary visual cortex—close to 30 have been identified in the monkey. Each small area of secondary visual cortex is a complete *retinotopic* map of the contralateral visual field, and each area responds best to different features of the visual signal—for example, to color, form, location, or motion. The areas of secondary visual cortex are located in **prestriate cortex** and **inferotemporal cortex**. Prestriate cortex is a band of cortex surrounding primary visual cortex; inferotemporal cortex is the cortex of the *inferior temporal gyrus*.

Visual information flows through the various areas of secondary visual cortex along numerous paths, each dealing with a different aspect of the visual world. These paths follow two general routes: a *dorsal route* and a *ventral route*. The dorsal route projects from primary visual cortex, to dorsal areas of prestriate cortex, to **posterior parietal cortex**—posterior parietal cortex is an area of association cortex that receives substantial auditory and somatosensory input in addition to its visual input. This dorsal route of visual projections is primarily involved in the perception of location and motion. In contrast, the ventral route projects from the primary visual cortex, to ventral areas of prestriate cortex, to inferotemporal cortex; and it is primarily involved in the perception of color and form. In other words, in general, the dorsal route system tells us where things are and where they are going, and the ventral route system tells us what they are.

Primary visual cortex

The areas of occipital cortex, one left and one right, that receive most of their input from the lateral geniculate nuclei of the thalamus; also referred to as *striate cortex*.

Prestriate cortex

The areas of cerebral cortex, one in each hemisphere, that surround primary visual cortex; the prestriate cortex of each hemisphere contains several different functional areas of secondary visual cortex.

Inferotemporal cortex

The cortex of the inferior temporal lobes; the inferotemporal cortex of each hemisphere contains several different functional areas of secondary visual cortex, each of which plays a role in the visual recognition of objects.

Posterior parietal cortex

The area of association cortex in the posterior parietal lobe of each hemisphere; it receives input from visual, auditory, and somatosensory systems and plays a role in the perception of location and motion.

Coloring notes

Use a different color for each of the four major cortical areas of the human visual system: *primary visual cortex, prestriate cortex, posterior parietal cortex, and inferotemporal cortex.*

